

## CASE STUDY

- 100% WOUND REDUCTION IN 18 WEEKS
- 17 ACTIGRAFT APPLICATIONS

### PATIENT:

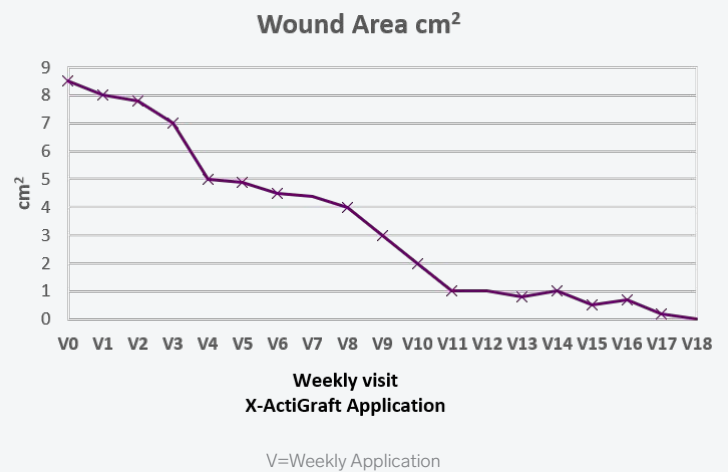
76 Year Old, Male

**PAST MEDICAL HISTORY:** PVD

### WOUND HISTORY:

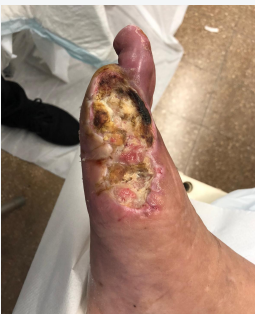- Post amputation of the great toe

**PAST TREATMENTS:** VAC, Advanced dressings



### ACTIGRAFT TREATMENT PROGRESSION:

Day 0



Week 18

